

**CASE REPORT**

## **Severe mitral valve stenosis post mitral valve repair, treated with balloon valvoplasty, a case report**

**KHOLOUD MOHAMMADDIN, HAMAD ALHABIB, FAISAL  
ALSMEDI, HALIA AL SHEHRI, ALTAF BUKHARI**

*Department of cardiac surgery, King Salman Heart center, King Fahad Medical city, Riyadh, Saudi Arabia.*

### **Abstract:**

*Symptomatic severe mitral regurgitation, initially treated with complex mitral valve repair, complicated by severe mitral stenosis, which resulted in severe hypoxia and lung failure that required extracorporeal membrane oxygenation. He was diagnosed with severe mitral stenosis and finally treated with a successful mitral valve balloon valvoplasty as the final solution and best solution.*

**Keyword:** *Mitral valve repair, Mitral valve stenosis, mitral Balloon valvoplasty, neo-cord mitral repair.*

### **INTRODUCTION**

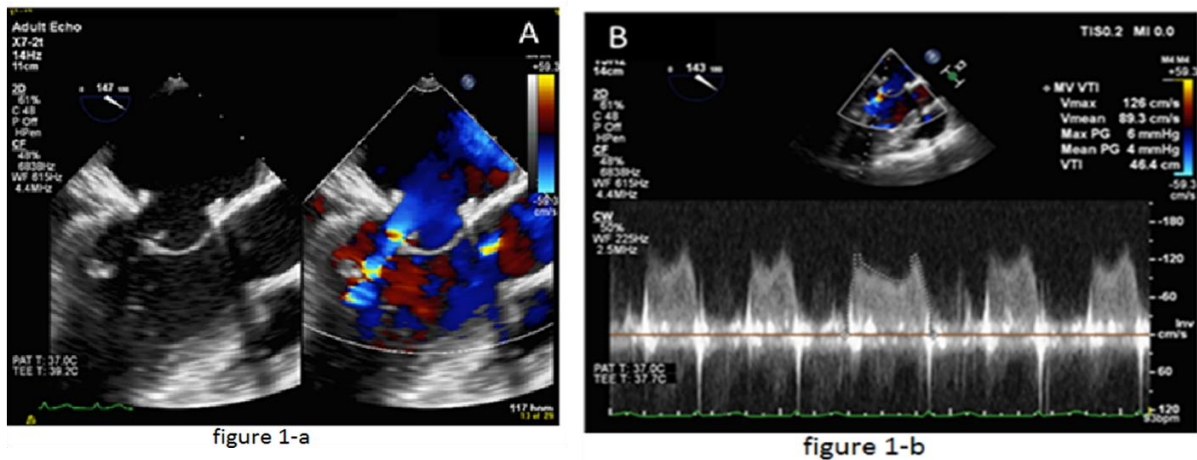
YOUNG 16 YEAR-OLD boy, referred for mitral valve repair. He had symptomatic severe mitral valve regurgitation (MR) with New-York heart association (NYHA) class III. His physical activity was limited due to his symptoms. He underwent a complex Mitral valve repair (MvR). Post operatively he developed severe mitral stenosis (MS) and developed severe hypoxia and lung failure that required Venovenous extracorporeal membrane oxygenator (ECMO). He was taken to the catheterization lab and a successful mitral valve balloon valvoplasty (MVB) was done. He recovered immediately and ECMO was removed next day. He was extubated in 24 hours and developed a mild middle cerebral artery (MCA) territory stroke that required rehabilitation post operatively with full recovery.

### **Case presentation**

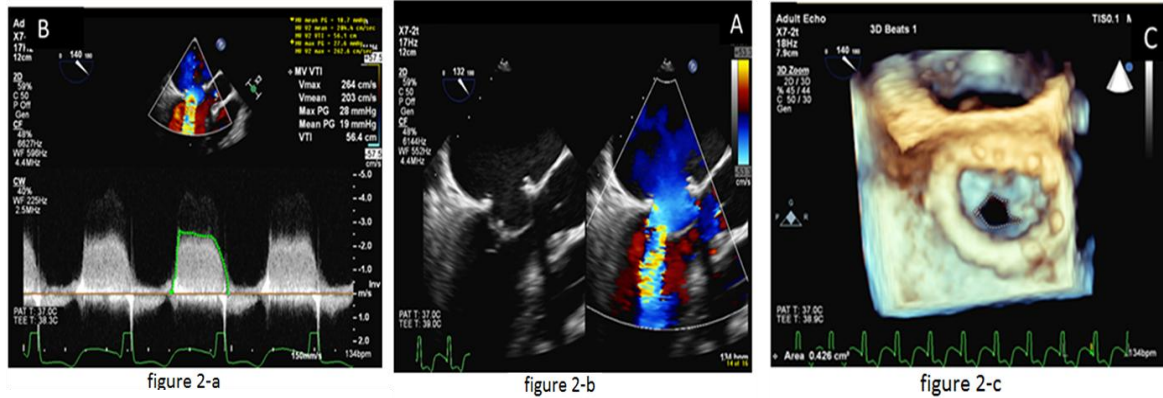
A 16 year-old boy, referred for mitral surgery. He had severe symptomatic MR with NYHA class III. He underwent pre-op TEE that showed severe MR with 2 jets: posterior and anterior. It also showed tethered posterior leaflet and a tiny prolapse of the tip of P2 (the original report). The surgery was planned to repair the posterior leaflet. Intra-operative assessment was different from the pre-operative and intra-operative TEE. The disease was mainly in the anterior leaflet and the posterior leaflet was normally small. The A2 and A3 and the 2 commissures were severely prolapsing. Also there was a cleft between A2 and A3. The MvR consists of 4 parts: annuloplasty rigid ring size 32, closure of A2 - A3 cleft, 2 Neo-cord to the anterior leaflet measure and adjusted intra-operatively, and finally kay (1,2) sutures to both

commissures to treat the commissural prolapse. Once the patient was off cardio-pulmonary Bypass (CPB), TEE showed no MR with MG across the mitral 4 mmHg (see figure-1-a and figure 1-b). He was taken to the intensive care unit (ICU) and extubated the same night.

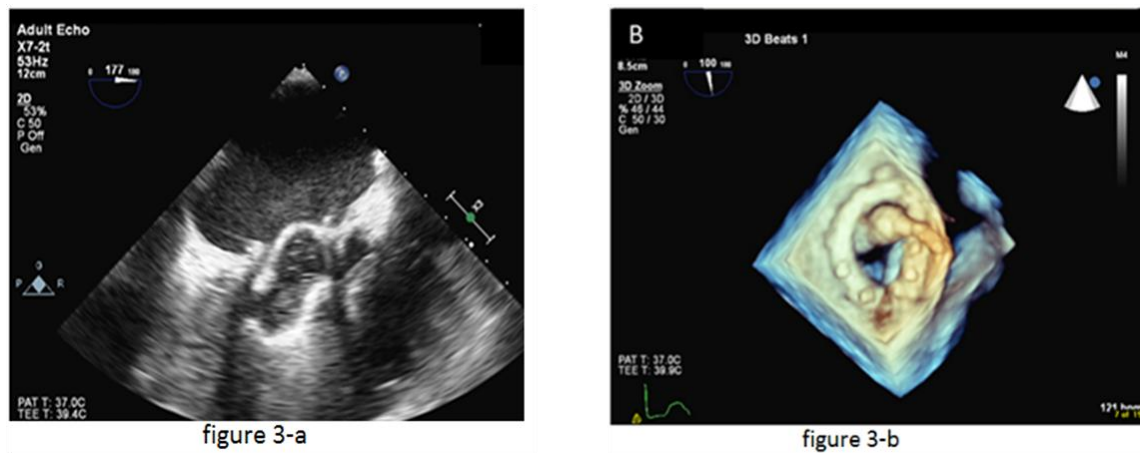
The next day he started to have severe respiratory distress that required re-intubation and progressed to severe lung failure that required Venovenous ECMO. TEE in the ICU showed severe mitral valve stenosis with MG of 17 mmHg across the mitral and valve area of 0.4 cm<sup>2</sup> (see figure-2-a, figure 2-b and 2-c). We thought in the beginning that all this is related to undiagnosed lung problems. Conservative management failed and we thought that we only have two options: redo the mitral valve surgically and replacing it and the second option is to balloon the mitral valve to open one of the kay-stitches-commissural repair. The cardiac team decided to do balloon valvoplasty. It was done with 24mm balloon (started with 20 then 22 then 24 inflation). The MG dropped from 17 to 5 mmHg and the mitral valve area increased to 1.4cm<sup>2</sup> (see figure 3-a, figure 3-b, and figure 4-a, figure 4-b). He tolerated the procedure very well and was weaned gradually from the ECMO and over 24 hours it was stopped and removed. Upon extubation, he showed signs of middle cerebral artery territory stroke with right hemiplegia and aphasia (figure 5). Later, he completely recovered from the stroke and required 2 weeks in the rehabilitation hospital.



**Figure1.** Post Mitral Valve repair. (a) Intraoperative Transesophageal echocardiogram post mitral valve repair showing opening of the mitral valve leaflets. (b) Continuous-wave Doppler across the mitral valve, demonstrating mean mitral gradient (4 mm Hg).



**Figure2.** Pre Mitral Balloon Valvuloplasty. (a) Transesophageal echocardiogram post mitral valve repair showing restricted diastolic opening of the mitral valve leaflets. (b) Continuous-wave Doppler across the mitral valve, demonstrating an elevated mean mitral gradient (18mm Hg). (c) Three-dimensional TEE images of the mitral valve as viewed from the left atrium demonstrating narrow mitral valve orifice in mid-diastole.



**Figure3.** Mitral Balloon Valvuloplasty. (a) Transesophageal echocardiogram during demonstrating inflation of the balloon within the mitral valve. (c) Three-dimensional TEE images of the mitral valve as viewed from the left atrium demonstrating balloon inflation.

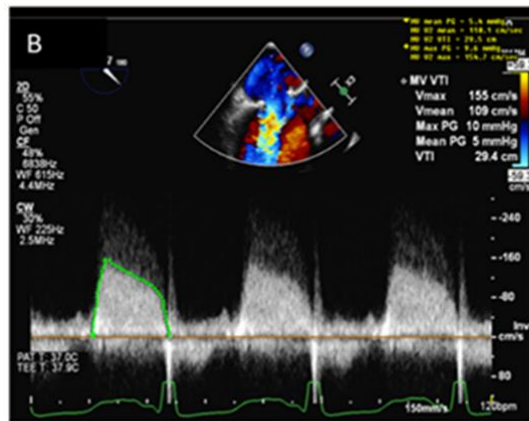


figure 4-a

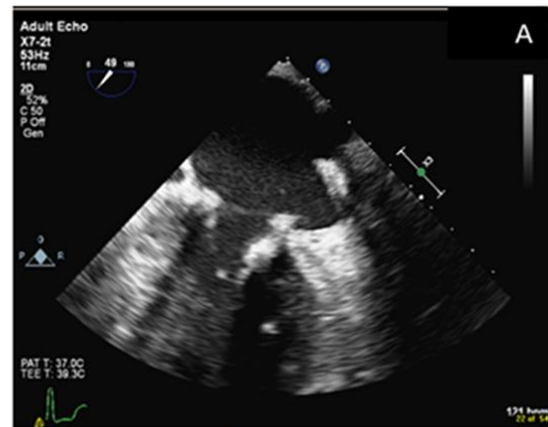


figure 4-b

**Figure 4.** Post Mitral Balloon Valvuloplasty. (a) Transesophageal echocardiogram showing increased diastolic opening of the mitral valve leaflets. (b) Continuous-wave Doppler across the mitral valve, demonstrating mean mitral gradient of 5 mm Hg.

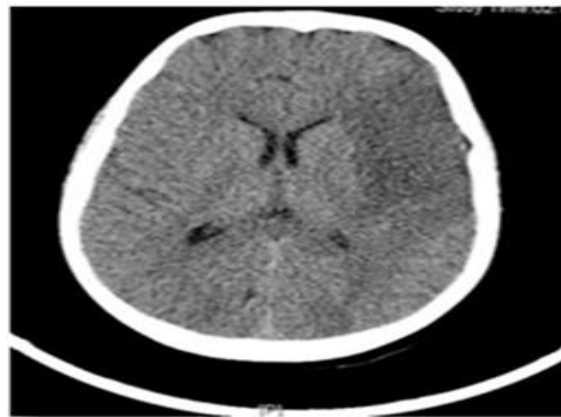


figure 5

**Figure 5.** CT scan showing Widespread acute infarct in the territory of the left MCA without hemorrhagic transformation

## DISCUSSION

Several complications after Mitral valve repair are known. Among them is repair failure that either result from poor or suboptimal technique that usually results from wrong pre-op assessment or missed pathology intra-operatively. The pathology of Mitral stenosis following mitral repair for a mitral regurgitation is poorly understood. The occurrence of mitral stenosis after mitral repair is not fairly studied, although its incidence can range from 9% up to as high as 54% (8). The TEE pre-operatively is crucial part of mitral valve surgery and vital to help the surgeon make an accurate diagnosis and final surgical plan as well as prognosis and post op care (9). Only a few authors have reported this rare post-operative complication.

In one study, 500 patients underwent mitral valve repair for myxomatous or ischemic mitral regurgitation and the author reported only 4 patients having mitral stenosis post-operatively (5). Later, three of these patients underwent a mitral valve replacement due to the severity of their symptoms. Another study who included a total number of 552 patients diagnosed with mitral regurgitation and underwent mitral valve repair. 9 out of those patients underwent a reoperation for mitral stenosis before being discharged from the hospital. The author did not specify the severity of symptoms in these patients. (6). Seunghwan Song, et al, reported 2 patients with mitral stenosis following mitral valve repair; one of the patients being a 5 year old child (7). Both patients underwent another redo mitral valve repair. The study was also was concerned about a recurring mitral stenosis, but follow up with these two patients showed minor progression of stenosis and regurgitation.

Our patient had a rare but significant complication of aggressive mitral valve repair. This complication was managed with a multidisciplinary team. At the end, he had the best benefit of mitral repair at this age group which is ability to grow and avoiding mechanical valve in this active age.

## CONCLUSION

A rare and interesting complication that occurred after aggressive MVR. A 16 year-old boy, referred for severe mitral regurgitation surgery. He had a complex anterior leaflet repair, annuloplasty rigid ring, neo-cords and KAY-stitches commissural closure. Intra-operatively the mean gradient (MG) was 4mmHg (see figure-1). Post operatively he had severe hypoxia requiring veno-venous ECMO. A repeated transesophageal echocardiography (TEE) showed severe MS with MG and mitral valve area of 18 mmHg and 0.4cm<sup>2</sup>, respectively (figure-2-a). A balloon valvoplasty was done to the Mitral valve as it was the only reason that could explain this clinical features. After the balloon valvoplasty, he came off ECMO and was extubated in 24 hours. After 3 weeks he completely recovered.

## Acknowledgment

We are grateful to the entire team in the operating room and the cardiac catheterization staff who worked as one team and made this rare successful event possible.

## REFERENCES

- [1] Kay JH, Maselli-Campagna G, Tsuji KK: surgical treatment of Mitral insufficiency. *West J Surg Obstet Gynecol.* May-Jun 1964;72:144-9. Accessed on July, 2016.
- [2] Kay JH, Maselli-Campagna G, Tsuji KK: surgical treatment of tricuspid insufficiency. *Ann surg.* 1965. 162:53-58. Accessed on July, 2016.
- [3] David TE, Armstrong S, Sun Z, et al: Late results of mitral valve repair for mitral regurgitation due to degenerative disease. *Ann Thorac Surg* 1993;56:7-14. Accessed on July, 2016.
- [4] Fernandez J, Joyce DH, Hirschfeld K, et al. Factors affecting mitral valve reoperation in 317 survivors after mitral valve reconstruction. *Ann Thorac Surg* 1992;54:440-8. Accessed on July, 2016.
- [5] Mohamed F Ibrahim, Tirone E David. Mitral stenosis after mitral valve repair for non-rheumatic mitral regurgitation. *Ann Thorac Surg.* January 2002;73:34-6. Accessed on July, 2016.
- [6] Riegel AK, Busch R, Segal S, et al. Evaluation of Transmitral Pressure Gradients in the Intraoperative Echocardiographic Diagnosis of Mitral Stenosis after Mitral Valve Repair. *PLoS ONE* 2011. 6(11): e26559. Accessed on July, 2016.
- [7] Seunghwan Song, Seong Ho Cho. Repair of mitral stenosis due to pannus formation after duran ring annuloplasty. *Ann thorac surg* 2010;90:e93-4. Accessed on July, 2016.

- [8] Muhammad Shabsigh, Cassidy Lawrence. Mitral valve stenosis after open repair surgery for non-rheumatic mitral valve regurgitation. A review. *Front cardiovasc med.* 2016, 3: 8. Accessed on July, 2016.
- [9] Galhardo Jr C, Botelho ESL, Diego LAS – Intraoperative Monitoring with Transesophageal Echocardiography in Cardiac Surgery. *Rev Bras Anesthesiol* 2011; 61: 4: 495-512. Accessed on July, 2016.